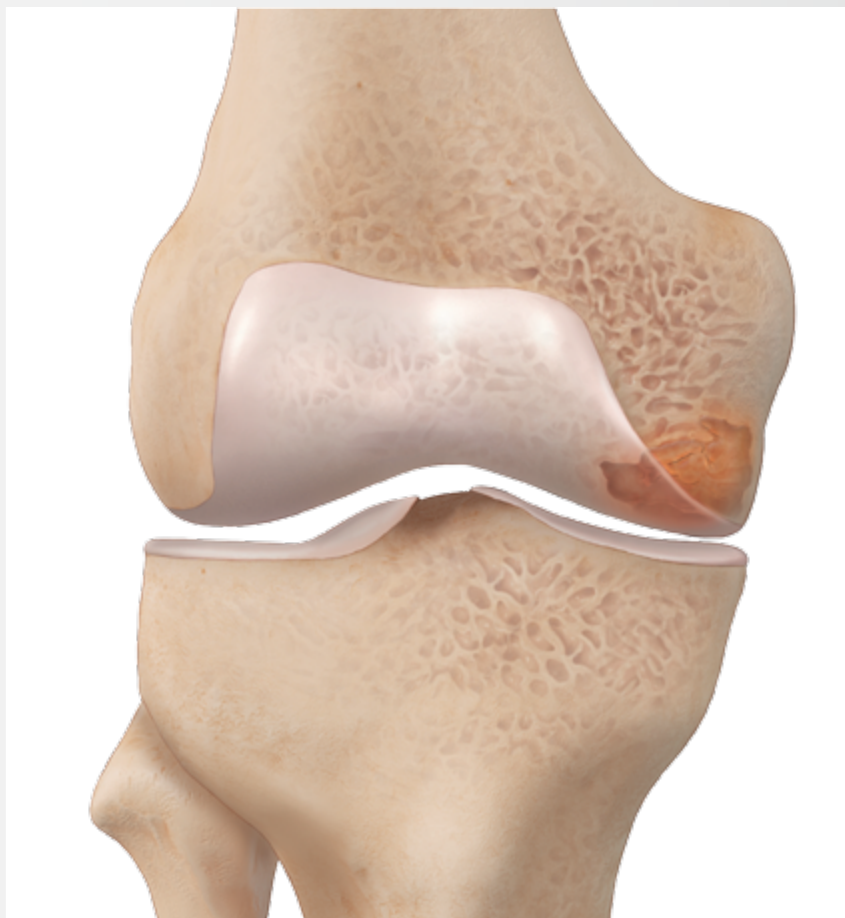

Intraosseous Bio Filler

Surgical Technique



Intraosseous Bio Filler Surgical Technique

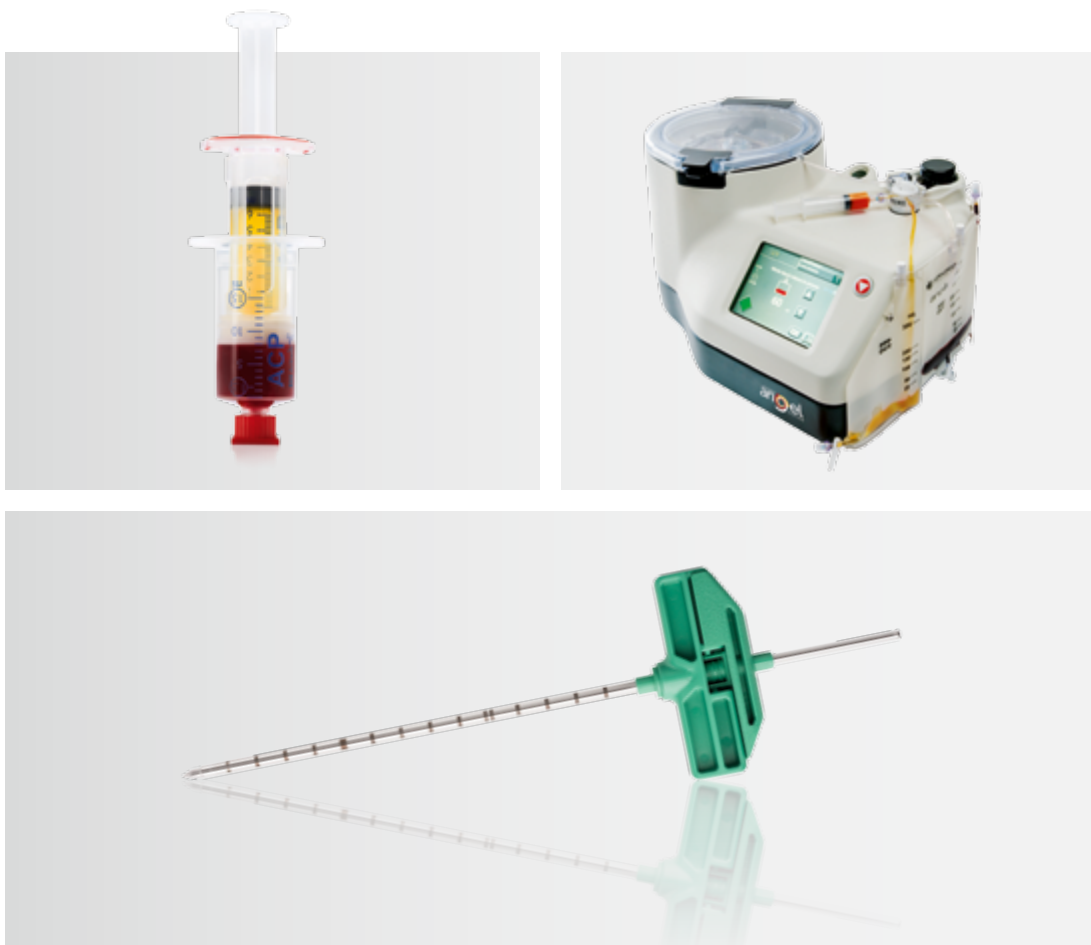
Introduction

The Intraosseous Bio Filler technique is the treatment of bone pathologies resulting from acute or chronic injury, including bone marrow lesions and spontaneous osteonecrosis of the knee (SONK).

Healthy subchondral bone provides support for the overlying articular cartilage and acts like a shock absorber for mechanical forces transmitted during joint loading.¹ Diseased or overstressed subchondral bone, which is referred to as a bone marrow lesion (BML), is not able to remodel properly on its own compared with normal bone.¹ BMLs have been shown to be present in anterior cruciate ligament (ACL) rupture and to correlate with the presence of pain in knee osteoarthritis (OA), cartilage loss and bone attrition.¹⁻⁸ In the knee they occur femorally as well as tibially.¹

Biologic fluids such as platelet rich plasma (PRP) or bone marrow concentrate (BMC) and/or bone substitutes can be injected with a variety of delivery needles that Arthrex offers for gaining access to a tibial or femoral lesion.

The goal of this procedure is to encourage subchondral bone remodeling and to reestablish the integrity of damaged subchondral bone, while aiding the natural healing process to achieve normal bone anatomy and function.








Key Features

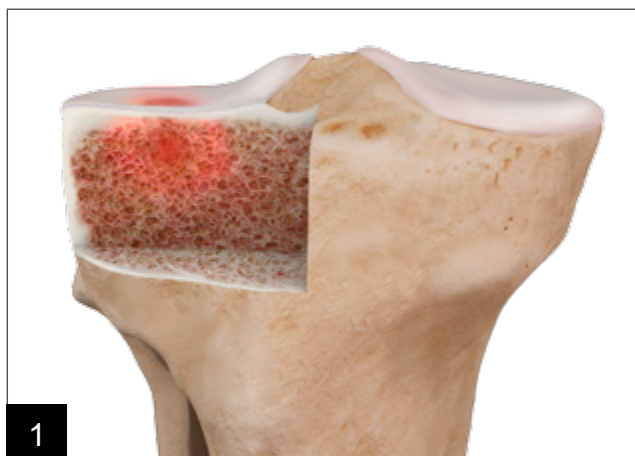
Delivery Needle:

- Diameter: 8 G – allows minimally invasive procedure
- Drill feature included – allows convenient access to the lesion and is compatible with Arthrex power tools

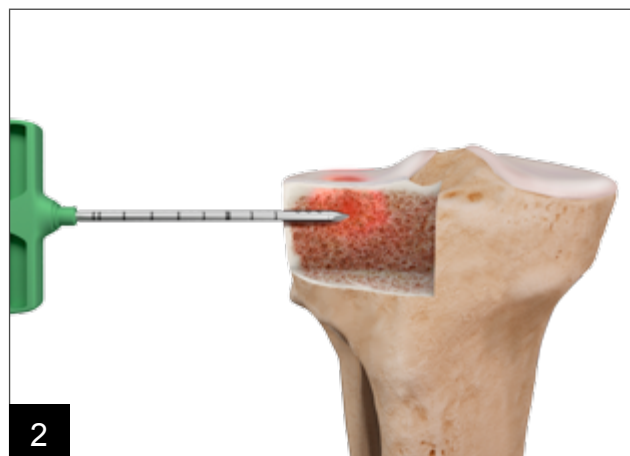
Three different delivery needles:

	Open Tip		Closed Tip
			
			
Length	15 cm	11 cm	11 cm
Item Number	RAN-815-OT	RAN-811-OT	RAN-811-CT
Application	Preferably for femoral lesions and contralateral access to the lesion	Preferably for femoral lesions and ipsilateral access to the lesion	Preferably for tibial lesions and ipsilateral access to the lesion

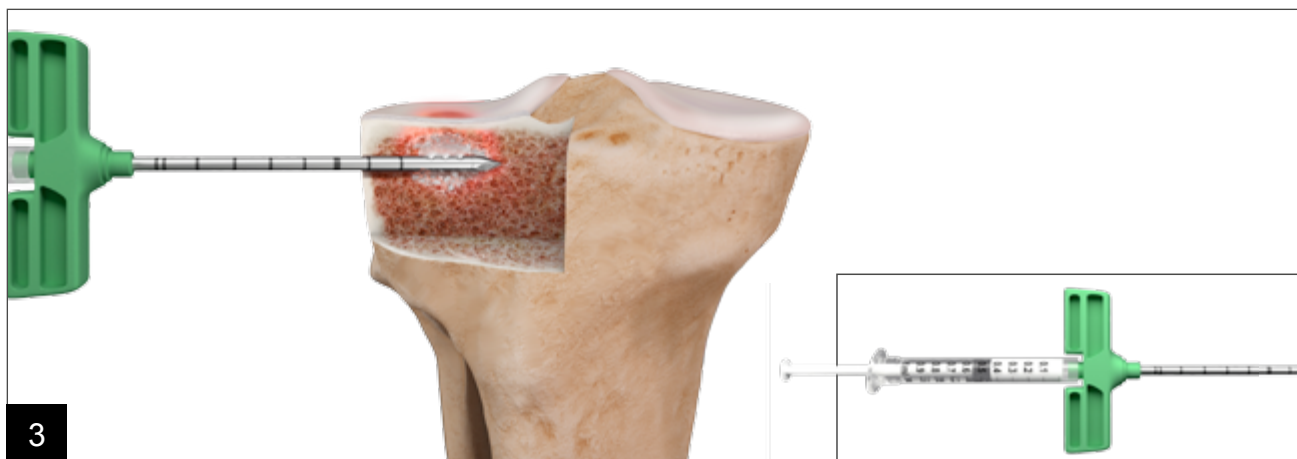Surgical Technique



Preoperatively: Identify the lesion with STIR* or fat-suppressed T2-weighted Magnetic Resonance Imaging (MRI). A BML appears as high signal intensity.⁹



Drill the delivery needle into the middle of the lesion under fluoroscopic guidance, based on the location of maximal lesion determined during preoperative MRI planning.



Remove the trocar.

- Inject PRP or BMC prepared with Angel-System into the lesion.
- Inject bone void filler to reestablish the structural integrity of the bone.

Note: It is recommended to transfer bone void filler to standard 1 cc syringes using a female-to-female Luer adaptor or a three-way stopcock before filling the lesion.

* Short T1 inversion recovery⁹ is an MRI sequence in which the lipid signal is suppressed and usually optimal contrast for lesion detection is provided.¹⁰

Ordering Information

Product Description	Item Number
Delivery needle, 8 G x 11 cm, open tip	RAN-811-OT
Delivery needle, 8 G x 11 cm, closed tip	RAN-811-CT
Delivery needle, 8 G x 15 cm, open tip	RAN-815-OT
Angel® system	ABS-10066
Angel® BMC kit with bone marrow needle	ABS-10072
Angel® PRP kit (incl. Angel® processing set)	ABS-10071
Anticoagulant ACD-A 20 ml	SAAV222.G00
Arthrex ACP® double syringe	ABS-10014
Centrifuge Hettich Rotofix 32A with swing out rotor 1324, 220 V	1206-Art
Centrifuge Hettich Rotofix 32A with swing out rotor 1324, 110 V	1206-01-Art
Counterweight for centrifugation of ACP double syringe, 15 ml	ABS-10027
Bucket for Hettich Rotofix 32A	1491
Screw cap for Hettich bucket	1492

*Note: 1 cc syringes and a female-to-female Luer connector are not provided. They must be provided by the facility where the surgery is occurring.

Please note that not all products advertised in this brochure / surgical technique guide may be available in all countries. Please ask the Arthrex Customer Service or your local Arthrex Representative before ordering if the desired product is available for delivery. Thank you very much.

References

1. Farr J, Cohen SB. Expanding Applications of the Subchondroplasty Procedure for Treatment of Bone Marrow Lesions Observed on Magnetic Resonance Imaging. *Oper Tech Sports Med* 2013; 21:138-143
2. Frobell RB, Roos HP, Roos EM, Hellio Le Graverand MP, Buck R, Tamez-Pena J, Totterman S, Boegard T, Lohmander LS. The acutely ACL injured knee assessed by MRI: are large volume traumatic bone marrow lesions a sign of severe compression injury? *Osteoarthritis and Cartilage* 2008; 16:829-836
3. Rosen MA, Jackson DW, Berger PE. Occult Osseous lesions Documented by Magnetic Resonance Imaging Associated with Anterior Cruciate Ligament Ruptures. *Arthroscopy: The Journal of Arthroscopic and Related Surgery* 1991; 7(1):45-51
4. Cohen SB, Sharkey PF. Subchondroplasty for Treating Bone Marrow Lesions. *J Knee Surg.* 2016; 29(7):555-563
5. Roemer FW, Neogi T, Nevitt MC, et al. Subchondral bone marrow lesions are highly associated with, and predict subchondral bone attrition longitudinally: the MOST study. *Osteoarthritis Cartilage* 2010; 18(1):47–53
6. Wluka AE, Wang Y, Davies-Tuck M, English DR, Giles GG, Cicuttini FM. Bone marrow lesions predict progression of cartilage defects and loss of cartilage volume in healthy middle-aged adults without knee pain over 2 yrs. *Rheumatology (Oxford)* 2008; 47(9):1392–1396
7. Felson DT, Chaisson CE, Hill CL, et al. The association of bone marrow lesions with pain in knee osteoarthritis. *Ann Intern Med* 2001; 134(7):541–549
8. Tanamas SK, Wluka AE, Pelletier JP, et al. Bone marrow lesions in people with knee osteoarthritis predict progression of disease and joint replacement: a longitudinal study. *Rheumatology (Oxford)* 2010; 49(12):2413–2419
9. Niall DM, Bobic VB. Bone Bruising and Bone Marrow Edema Syndromes: Incidental Radiological Findings or Harbingers of Future Joint Degeneration? *International Society of Arthroscopy, Knee Surgery, and Orthopaedic Sports Medicine*. Retrieved from: <https://www.isakos.com/innovations/niall>
10. Smith RC, Constable RT, Reinhold C, McCauley T, Lange RC, McCarthy S. Fast Spin Echo STIR Imaging. *Journal of Computer Assisted Tomography.* 1994; 18(2):209-213



This description of technique, including any post-op protocol, is provided as an educational tool and clinical aid to assist properly licensed medical professionals in the usage of specific Arthrex products. As part of this professional usage, the medical professional must use their professional judgement in making any final determinations in product usage and technique. In doing so, the medical professional should rely on their own training and experience and should conduct a thorough review of pertinent medical literature and the product's Directions For Use.

View U.S. patent information at www.arthrex.com/corporate/virtual-patent-marking

© Arthrex GmbH, 2017. All rights reserved. | www.arthrex.com | LT2-00070-EN_B